

Non-Conformational Traits

Gentle pecking would be considered a positive trait, as this activity indicates curiosity, friendliness and calmness. An exception is hard or violent pecking mischievously at the ears and eyes, etc. of the judge or participant. This should be grounds for down grading. Minor flare-ups of a raised neck, neck feathers and hissing toward other birds should not be cause for down grading. Running in a panic, jumping, kicking and fighting between birds is considered undesirable.

A 'good' bird should have a normal respiration rate and stand and walk in style (strut). A bird with superior conformation but undesirable behavior would be down graded and judged lower than a bird with good conformation and desirable behavior. Most all birds can be imprinted and learn to be very calm and well behaved and a participant should be rewarded for this achievement.

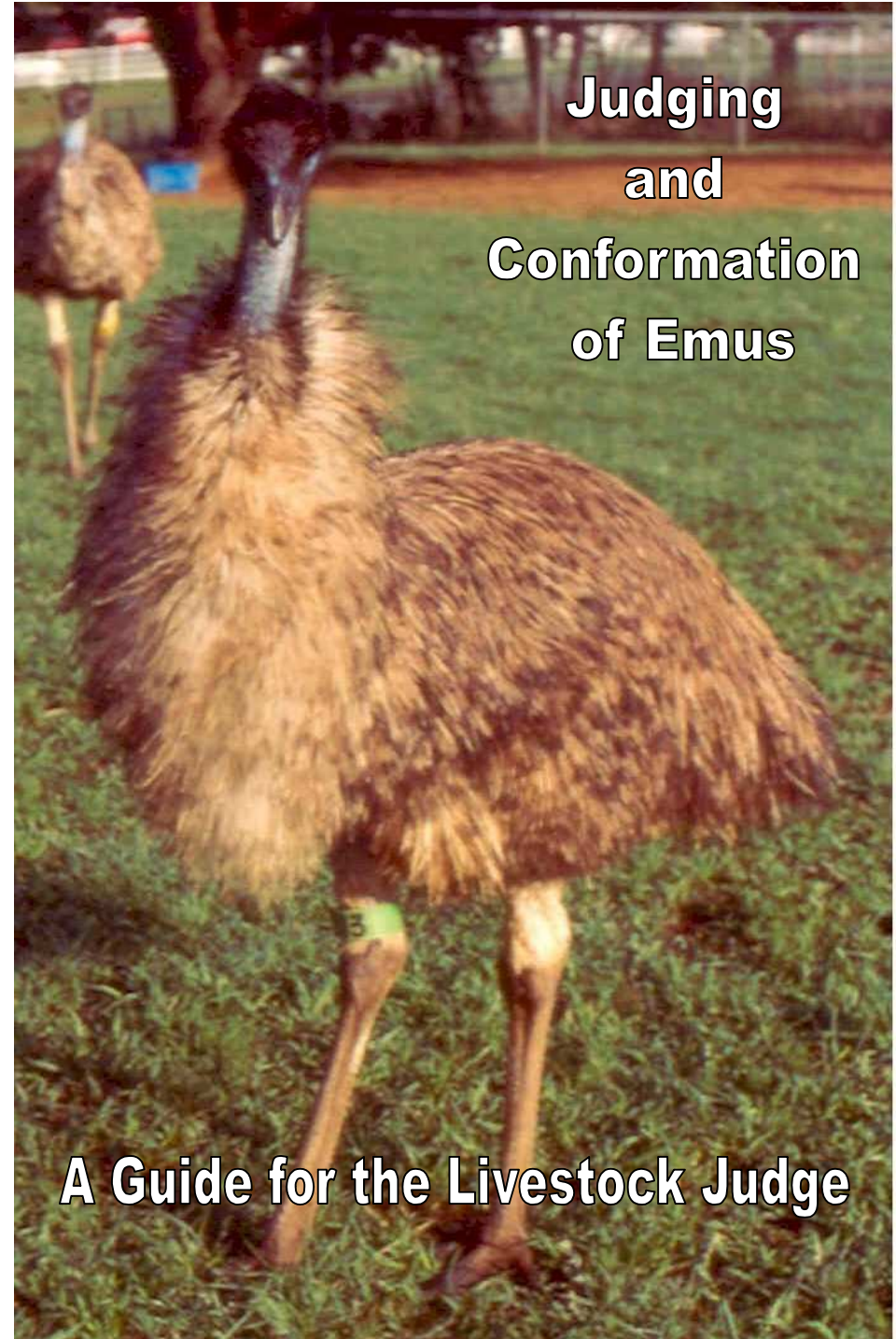
All birds should have documentation of age and sex.



©American Emu Association

All Rights Reserved

P.O. Box 224
Sixes, OR 97476
(541) 332-0675
Fax (928) 962-9430
<http://www.aea-emu.org>



Judging and Conformation of Emus

A Guide for the Livestock Judge

Judging and Conformation of Emus

Beak - The color should be black. The upper beak is a triangle shaped on cross section with the tip even or only slightly overlapping the tip of the lower beak. Serrations on the edge may or may not be present. Look for abnormal color, shape, size, lumps, scars, parrot beak, etc.

Nares – Nares, or nose openings are oval shaped on each side of the upper beak. These should be free of discharge and debris.

Eyelids – The lids may be solid black or have white regions. Eyelashes should be present. The lid margins should be even and retracted to expose the eyeball. Look for uneven edges, lack of lashes, lumps, scars, scrapes, droopy eyelids, etc.

Third Eyelid – This lid is normally retracted to the medial side of the eye and expands rapidly over the eye in response to objects nearing the eye.

Eyes – The eye should be oval. Evaluate for discharge, scars, cataracts, cloudiness, etc. Emu as chicks have brown eyes which become golden brown as they reach breeding age. As they get older, the eye color changes to golden orange. In blonde or white emus, the eyes may be blue.

Head – The head, including the beak, should appear to be the appropriate size for the body. The head should be rounded in shape. Flat, long-sloping or short-sloping foreheads are not normal. Also, look for scars, lumps, etc.

Mouth – The mouth should be opened and the tongue, esophagus, choanal slit and oral mucosa examined. Ulcers, white spots, excess mucous, blood, lumps and bright red or pale white mucosa are not normal. The tongue should have serrations and a pointed end.

Ear Canal – The normal location is behind the eye and beak on the side of the head at the level of the articulation of the upper and lower beak. Evaluate the size, shape, and feather coverts. The canal should be free of debris and discharge.

Skin – The skin color on the back of the head and upper neck is a variation of blue, white, tan and black which varies with age and breeding season. The skin in front of the neck should be evaluated for feather loss and scars due to fence rubbing. Skin over the rest of the body should be pinkish to white in color. Dry, scaly skin, scabs and scars from abrasions are not to be considered normal.

Feathers – Age will determine the normal feather qualities.

Chicks: From the time it is hatched until it is 3 months old, chicks will have short downy feathers in three colors running in stripes: white, black and brown.

Juveniles: After losing their stripes, they become a chocolate brown to black with feathers turning gray as they reach maturity. Shiny metallic black feathers indicate previous feather loss with regrowth or metabolic disorder and are not considered normal.

Adults: After 2 years of age, feathers become more consistent. The color varies from light to dark charcoal gray with black accents on the tips. There are two feather vanes per shaft or follicle. The feathers on the upper neck and head are hair-like, curly and black in color. The body feathers should be clean, free of lice, long shiny and fluffy. Tail feathers should be short and ruffled in laying, breeding hens and long and fluffy in the off-season. Shiny metallic black feathers indicate previous feather loss with regrowth or metabolic disorder and are not considered normal except in the case of breeding female with this feather regrowth in one area of her neck or back where the male has been pecking her during breeding activity.

Neck – The neck should be carried upright with a downward slope from the back and backward curve toward the head. The neck should be palpitated to evaluate the straightness and determine if lumps or other anomalies are present. If the bird has just eaten, the food may appear as a lump.

Back – The vertebrae, synsacrum, or pelvis, and muscles form the back. The back should be straight, sloping slightly upward to the coxofemoral joint where the femur of the leg attaches, then should slope downward at a 30° to 40° angle. Evaluate for curvatures, abnormal slopes and unproportional structures.

Height – If height is to be evaluated, it should be measured from the ground to the top of back over coxofemoral joint. This site will fluctuate during the year due to the amount of fat on the back. Most emu will vary between 40 to 43 inches in this area. If height is to be evaluated, so should width.

Wings – Located on each side of the chest. A single claw per wing is normal. Evaluate for abrasions, fractures, etc. Emus that have lost a wing due to fights or those born without wings should be penalized.

Legs – The leg is composed of 3 major bones: the femur, which attaches to the coxofemoral joint and should slope downward and forward at a 45° angle; the tibia, which starts the most straight downward and slightly backward direction of the leg and is covered by heavy muscles and feathers on the skin; and the metatarsal bone, which is directly below the tibia. The skin over the metatarsal in adults should have a row of raised scutes on the back side. The legs should be straight, symmetrical and sound. Evaluate for lameness, discoloration, bowing, inward or outward rotation, thickness of the bones and lumps, cuts, scars, etc. There are two genetic types of birds: Type 1: the metatarsus bone is long with a small diameter. Type 2: the metatarsus bone is short with a large diameter. If birds of two types are interbred, the offspring will have an intermediate sized metatarsus. The metatarsus is the bone between the hock joint and ankle.

Toes – There are three toes per foot. The central toe is the longest and inside toe is the shortest. Each toe should have a claw. The claw size should correspond to the size of the toe. The claws should be straight or with only a minor outward curve. The pads under the toes should be smooth and be only slightly wider than the toe itself. Abnormal traits would be crooked or fractured toes, cuts, lumps, scars or crooked, scaly or overgrown toe claws, etc.

Cloaca – The cloaca should be visually examined for prolapse. Manual examination for determining sex of the emu is not recommended, as this is stressful for the bird.

General Body – The body should be accessed by palpitation for the degree of body fat and overall condition. Fat is deposited on the back, chest, and abdomen. The abdomen should be palpated and evaluated for hernias, body fat and fullness. The depth of the body should be evaluated, i. e., the distance from the top of the back to the bottom of the belly. The overall body length can be determined by measuring the distance from the front of the chest to the end of the pelvis.

Additions Related to Age and Sex

Chicks – Feather changes as stated above. Evaluate umbilicus for abscess, scabs, etc. Eye color is darker.

Females – Feathers as stated above. Pendulous skin below neck is normal. From puberty to 3 years of age, the pendulous pouch should be much larger than in hens that are older, as the size normally reduces after 4 years of age. Females may or may not be larger in body size than males.

Pairs - If evaluating pairs, size differences between the two should not be a consideration. The pair should get along well together.

